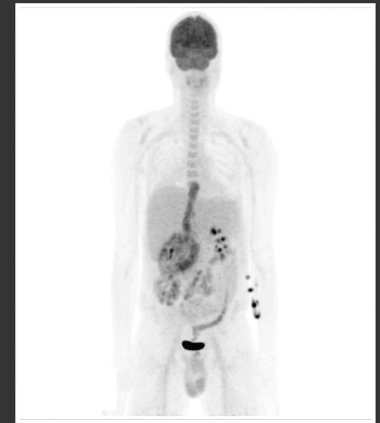
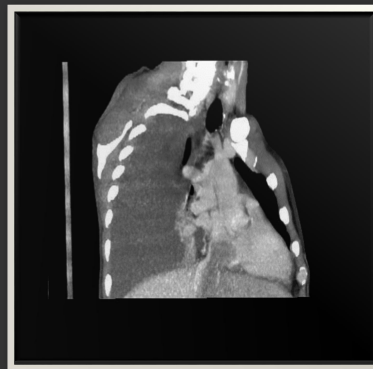
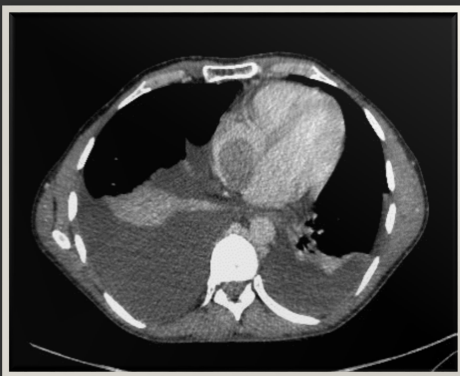Multimodality Imaging in Cardio-Oncology: Para-caval leiomyosarcoma invading the right heart

Csilla Jozsa 1, Emma Cheasty 1, Jose Bingcang 2, J Malcolm Walker 2, Chirag Shah 3, Sanjeev Bhattacharyya 1, Arjun K Ghosh 1,2

1 Barts Heart Centre, St Bartholomew's Hospital, 2 University College London Hospital, 3 Kings College Hospital, London, United Kingdom

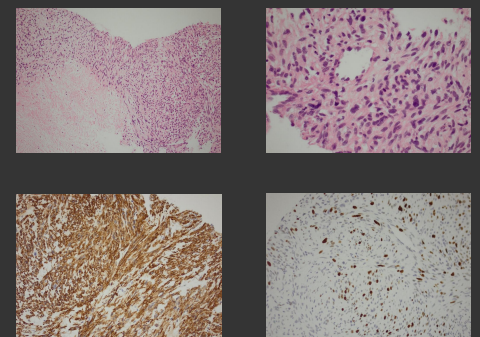
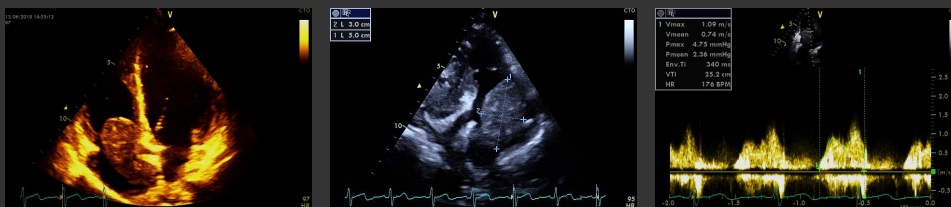
Introduction: retroperitoneal sarcomas are rare aggressive soft tissue tumours that represent 0.1%-0.2% of all malignancies. Leiomyosarcoma is one of the most common sarcomas in the retroperitoneum with occasional extension into the inferior vena cava.



We present the case of a 46-year-old man with a history of intermittent abdominal pain, non-cardiac chest pain and mild breathlessness. A large subhepatic mass involving the retroperitoneal compartment with direct invasion of the inferior vena cava and right atrium was found on abdomen-pelvis CT scan. There was no distant metastasis on PET-CT.

Transthoracic echocardiography showed a large, mobile mass with a maximum expansion of 3.0x5.0 cm attached by a stalk to the IVC in the right atrium. During atrial systole the mass moved into tricuspid annulus causing no significant obstruction.

Histology confirmed the features of leiomyosarcoma.



The patient was inoperable due to advanced stage. His case was discussed in the cardio-oncology MDT also involving the intensive care team. It was felt that the first cycle of chemotherapy (Doxorubicin and Ifosfamide) carried a high risk of arrhythmia, major bleeding, heart failure and pulmonary embolism and the patient should have treatment in a level 2 monitored environment. In this setting he received the first cycle of chemotherapy without any complications.

Conclusion: our case illustrates the importance of multimodality imaging and multidisciplinary team involvement in dealing with this challenging diagnosis and treatment.